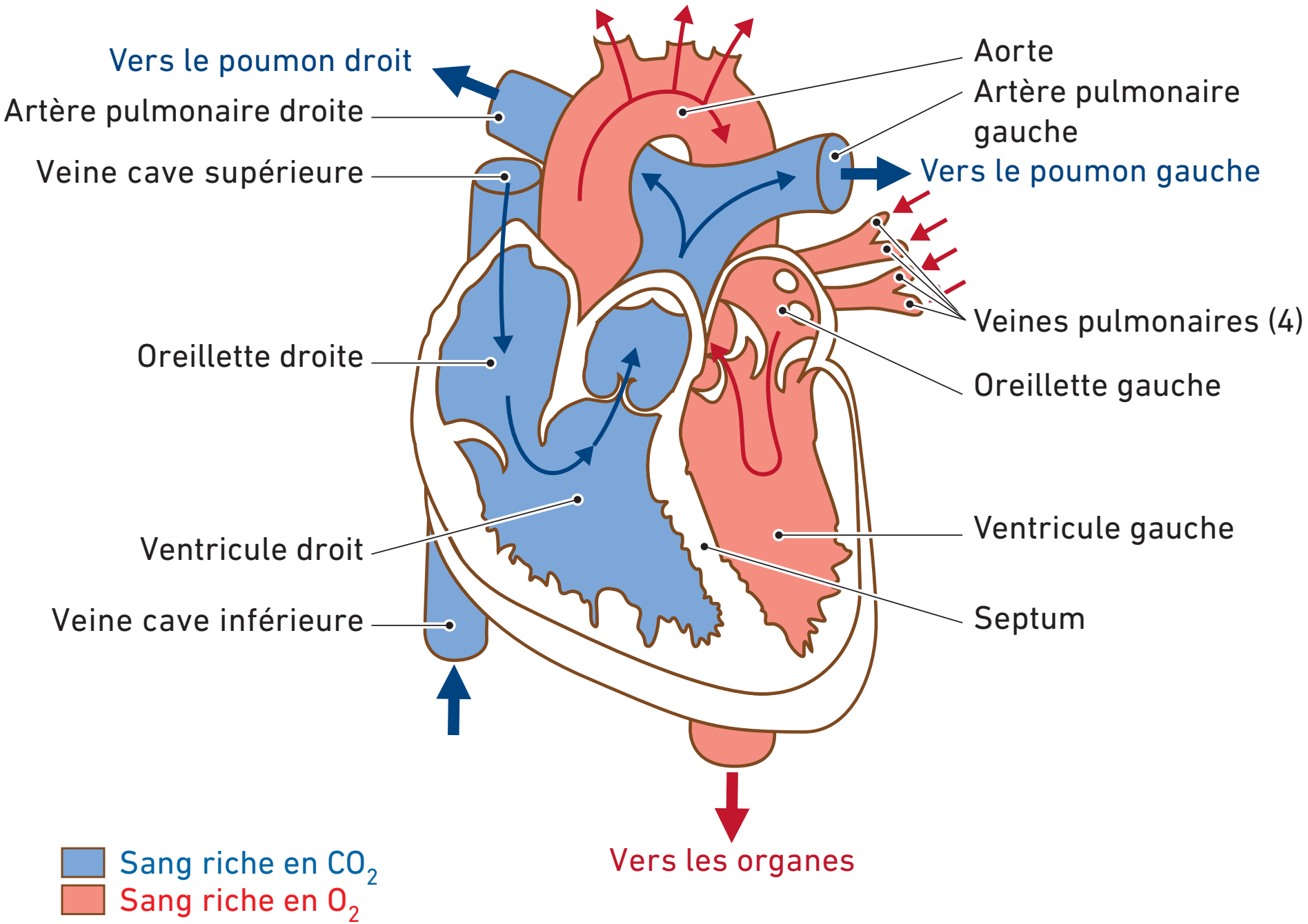Coupe frontale du cœur